

Intralesional biological glue - a new perspective for the prevention of bisphosphonate-induced osteonecrosis of the jaw

Carine Tabarani,¹ Fawzi Riachi,² Sophie Lejeune³

Abstract

Bisphosphonates are considered nowadays as drugs responsible in the modulation of bone-turnover, and that, by inhibiting the osteoclast-activating factor, will directly influence bone remodeling.¹⁰ These inhibitors of osteoclasts have been shown to alleviate many devastating consequences associated with corticosteroid-induced osteoporosis, but are still the main cause of osteonecrosis of the jaw. This article addresses a technique used in the prevention of bisphosphonate-induced osteonecrosis and in the management of the care of patients with corticosteroid-induced osteoporosis who are receiving bisphosphonates and who are at risk of developing bone osteonecrosis.

Keywords

Bisphosphonates-induced osteonecrosis, bone turnover, osteoclasts, corticosteroids.

Bisphosphonates are synthetic, non-metabolized analogues of the naturally occurring inorganic pyrophosphate¹² and have an elevated affinity for bone due to their R1-side chain, the various bisphosphonates approved for clinical use, differ based on structural alterations of the R2-side chain.

Osteonecrosis of the jaw, also called osteonecrosis and bisphosphonate-associated osteonecrosis,²⁴ secondary

to bisphosphonate therapy, both intravenous and oral, is becoming an increasingly reported complication following dental extraction therapy, and has been seen with a higher rate in mandible (63%) than in maxilla (38%).⁶

We can distinguish three generations of bisphosphonate. The first is formed of the non-aminobisphosphonates (Etidronate, Clodronate), the second corresponds to the amino-bisphosphonates (Pamidronate, Alendronate) that are 100 to 500 times more powerful, and the third generation (Ibandronate, Zoledronic acid and risedronate) is 10 to 20 times more powerful than the previous generation.²⁶

Marx in 2003 described the first case of osteonecrosis of the jaw (ONJ) associated with bisphosphonate therapy since then the number of cases reported is increasing and has become "growing epidemic".²

Intralesional biological glue is considered in these cases for its capacity of homeostasis, fixing, adhesion and hermeticity of tissue and in enhancing the healing of surgical wounds.

¹ Carine Tabarani, Dr.Chir.Dent., DES Odont.Chir., DU Patho.Orale Senior lecturer topographical anatomy Division, fellow department of Oral Surgery, Saint-Joseph University Faculty of Dental Medicine, Beirut, Lebanon

² Fawzi Riachi, Dr.Chir.Dent., CES Odont.Chir., CES Perio. Chairperson of the Lebanese Society of Oral Surgery, Chairperson, Department of Oral Surgery, Saint-Joseph University Faculty of Dental Medicine, Beirut, Lebanon

³ Sophie Lejeune, DDS, DESCO; Assistant Professor Department of Oral Surgery, Faculty of Dental Medicine, Rennes University, France.

Corresponding Author

Dr. Carine Tabarani
Email: ctabarani@hotmail.com

The action of the biological glue will reproduce the last stage of the coagulation process, where the fibrinogen will be transformed to insoluble fibrin influenced by the action of thrombin and factor XIII. The thrombin, fibrin and factor XIII will enhance fibroblastic proliferation.¹

The aprotinine added to the fibrin glue will inhibit the fibrinolysis induced by the plasmatic proteases for a period extending to 15 days.

The availability of intralesional biological glue in hospitals, prompted us to evaluate its effect on patients undergoing bisphosphonate treatments. We will mention a case report that serves to alert surgeons to the potential complication of bone necrosis in patients receiving bisphosphonate therapy, and proposes a guideline for prevention of bone osteonecrosis of the jaw.

Clinical Case

A 47-year-old man consulted us for a spontaneous irradiating pain in the anterior maxillary region. Clinical examination showed a fractured 22 tooth that revealed to be non vital (Figure 1).

Panoramic radiograph was assessed where we recognized the 22 fractured tooth with a limited radiolucency image in the apical region (Figure 2).

Interrogation of the patient revealed a history of asthma for the past 10 years, that was treated with corticosteroid therapy, which, with time, caused corticosteroid-associated osteoporosis.

The patient recalled treatment by bisphosphonates (Didronel for 3 years, that was stopped 6 years previously; Bonviva and Fosamax orally administrated for the past 4 years and Aredia administered intravenously for the past 9 years) (Table 1).

Conservative extraction of the 22 tooth was decided with the use of intralesional biological glue.

A loco-regional peri-apical without epinephrine analgesia

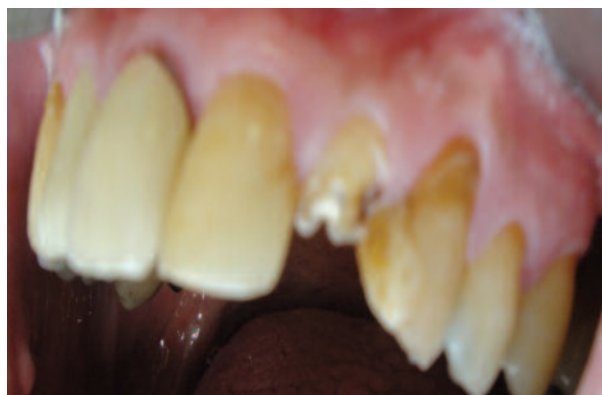

Figure 1: Clinical presentation of the fractured 22 tooth.

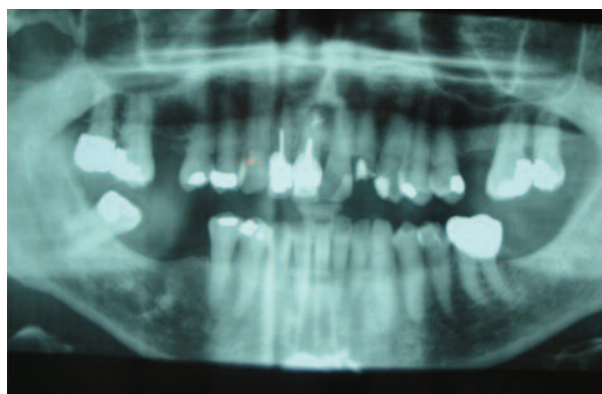


Figure 2: Panoramic radiograph showing the fractured 22 tooth with a radiolucent area in the apical region, necessitating a non invasive extraction procedure.

xylocaine (Pierre Rolland), was assessed in order to keep the blood flow in the region, and a non invasive extraction was done (Figures 3 and 4).

A homeostatic sponge was fixed by an absorbable 4(0) vicryl rapide sutures (Figures 5 and 6). In order to enhance the healing, the whole entity was covered by biological glue

Table 1: Bisphosphonate molecules classification as listed in the clinical case:

Brand name	Generic name	Administration	Dosage
Bonviva	Ibandronate	Oral	150 mg/month
Didronel	Etidronate	Oral	80 mg/week
Fosamax	Alendronate	Oral	70 mg/week
Aredia	Pamidronate	Intravenous	4 mg/month

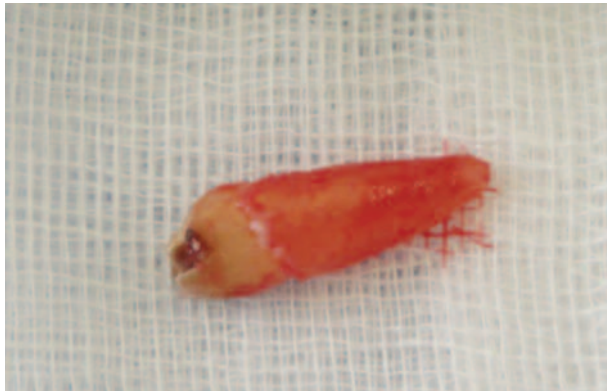

Figure 3: After conservative surgical procedure, the 22 tooth was removed.

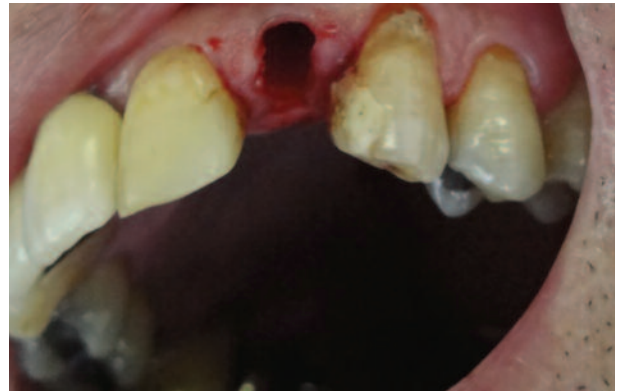

Figure 4: Intraoral presentation of the extraction socket, note the low bleeding rate in this area.

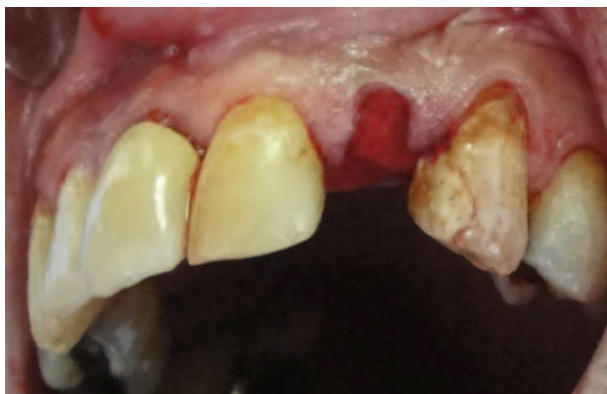

Figure 5: Hemostatic sponge placed in order to enhance the healing rate in this region.

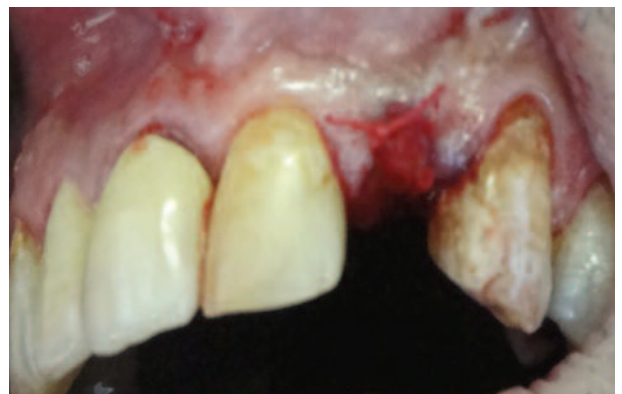

Figure 6: 4(0) absorbable vicryl rapide (polyglactin 910) sutures were added to the hemostatic sponge to adapt it in place and lower the soft tissue trauma rate.

(Figure10) in order to enhance the healing process, isolate the surgical wound from saliva and risk of infection and, in particular, give the bone the suitable time to heal by proliferation of the connective tissue.

A 14-day postoperative antibiotic treatment (Amoxicillin 1g) was prescribed in order to prevent any infection complications that could be added to the preexisting risks. A 30-day postoperative recall showed no complications with favorable wound healing.

Discussion

Bisphosphonates are agents used for the prevention and treatment of corticosteroid-induced bone loss, Paget disease, cancer-induced bone diseases,¹⁵ multiple myeloma and osteolytic bone metastases.⁷

Osteonecrosis of jaw bones represents the main undesirable effect of treatment using nitrogen-containing bisphosphonates, therefore we need to distinguish types found in cancer patients from those found in patients treated for osteoporosis.^{3,4,18,19,20,21}

The mechanism by which bisphosphonates inhibit osteoclast action appears to differ between amino- and non-amino-bisphosphonates.^{7,16,25}

More risks were found in intravenous therapy than oral medications.^{14,15}

The clinical aspects of presentation of bone osteonecrosis associated with bisphosphonates described in literature are diverse, sometimes very extensive and some other limited to the extraction socket.

A review of the literature revealed that bone osteonecrosis

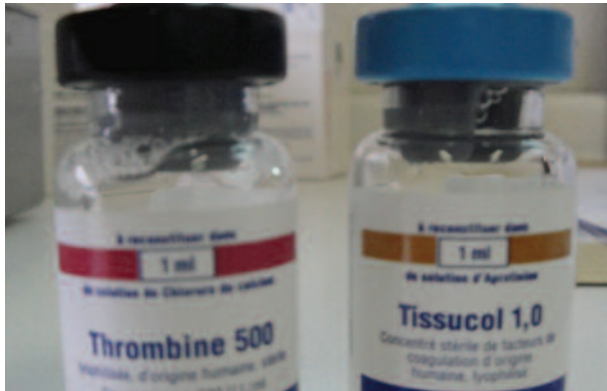

Figure 7: Solutions formed from Calcium chloride (tube1), and Aprotinine (tube2).



Figure 8: The Fibrotherm will guide the 4 tubes to the ambient temperature (37°C) by using a thermostated agitator.

is much more frequent in females. This could be due to the fact that women are more frequently treated with bisphosphonates in cases of post menopausal osteoporosis.

However, the first description of bisphosphonate associated osteonecrosis was made by Marx.²

Bisphosphonate treatment has shown to induce significant amounts of osteoclastic death, and therefore inhibition of the remodeling bone cycle. Moreover, it has shown a significant antiangiogenic action that will lead to the reduction of the wound healing rate.^{5,13,17,22,26} Some theories have noted that bone osteonecrosis by bisphosphonates is silently in evolution and that the act of extraction will reveal it clinically.

Regarding surgical treatment, Marx does not recommend surgery for the treatment of bone osteonecrosis since it will possibly lead to more exposed bone.¹¹

The majority of reported cases of bisphosphonate-

associated osteonecrosis of the jaw have been diagnosed after dental procedures, such as tooth extraction.⁶ We should therefore incorporate expert panel recommendations into clinical decision-making when faced with patients undergoing bisphosphonates treatment.

Despite that recommendations for dental management of patients taking bisphosphonates have developed,⁹ there are still no specific guidelines existing for the management of patients taking bisphosphonates.⁶

Non-invasive extraction site healing involves osteoclastic and osteoblastic activity to remodel the tooth socket, and the action of bisphosphonate in the region with the bacterially infested saliva, results in alteration of the healing process. Therefore the use of biological glue in the present case positively influenced the prognosis. This observation could also be explained, not only by the biological action of the glue, but also by the different characteristics of the bone

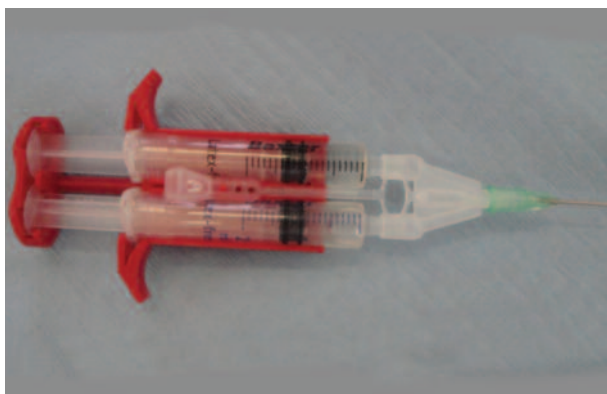

Figure 9: The Duploject : A syringe-holding system that will help to apply an equal proportion of biological glue to the extraction socket area.

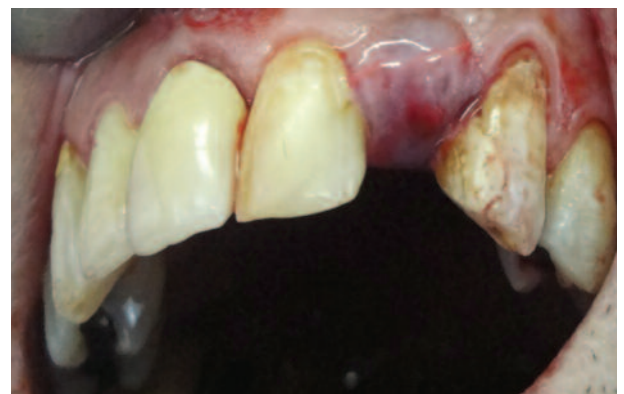

Figure 10: Behavior of biological glue in isolating and stabilizing the surgical wound.

tissue, which is less compact and more vascularized in the maxillary region.

Although this report serves to alert clinicians about the capacity of preventing bisphosphonate-associated osteonecrosis of jaws by using a biological glue and a non invasive extraction technique, many questions remain concerning the interruption of the medication and the period recommended for healing.

Until more is known, authors recommend that measures should be taken to prevent osteonecrosis in patients at risk, including identifying patients with a history of bisphosphonate therapy before undergoing any dental procedure.²³

This article confirms that intralesional biological glue could enhance bone healing by isolating the wound from the surrounding oral environment and in preventing the fibrinolytic stage due to the presence of aprotinin, which will lead in patient undergoing bisphosphonates treatment to prevent jaw osteonecrosis by enhancing fibroblastic proliferation.⁸

Conclusion:

Osteochemonecrosis of the jaw is considered a complication which, in general terms, shows an uncertain prognosis with low healing rates.

This article supports the fact and need to establish preventive measures in all patients treated with bisphosphonates, in order to prevent bisphosphonates-induced osteonecrosis of the jaws.

Further research is required for a better understanding of the role of biological intralesional glue in the prevention of osteonecrosis of the jaws in patients undergoing bisphosphonate treatment.

As more data become available, guidelines may need to be amended.

Complete prevention of this complication is not currently possible, however the use of intralesional biological glue can be considered a vital technique for the prevention of bisphosphonates-induced osteochemonecrosis of the jaw.

References:

1. Laki K., Lorand J. On the solubility of fibrin clots. *Science* 1948;108:280.
2. Marx RE. Pamidronate (Aredia) and Zoledronate(Zometa)

induced avascular necrosis of the jaws :agrowing epidemic. *J Oral Maxillofac Surg* 2003;61(9):1115-7.

3. Wood J. , Bonjean K., Ruetz S., Bellahcene A., Devy L. Novel antiangiogenic effects of the bisphosphonate compound zpledronic acid. *J Pharmacol Exp Ther* 2002;302:1055-61.

4. Zarychanski R.,Elphee E,Walton P.,Johnson J. Osteonecrosis of the jaw associated with pamidronate therapy. *Am J Hematol* 2006;81(1):73-5.

5. Abi Najm S.,Lysitsa S.,Carrel JP,Lesclous P,Lombardi T., Samson J. Osteonecroses des maxillaires chez des patients traites par bisphosphonates. *Presse Med* 2005;34:1073-77.

6. Migliorati CA., Casiglia J., Epstein J., Jacosen PL., Siegel MA.,Woo SB. .Managing the care of patients with bisphosphonates associated osteonecrosis:an American Academy of Oral Medicine position paper. *J.Am Dent Assoc* 2005;136(12):1658-68.

7. Ruggiero SL., Mehrota B., Rosenberg TJ., Engroff SL. .Osteonecrosis of the jaws associated with the use of bisphosphonates :a review of 63 cases. *J Oral Maxillofac Surg* 2004;62(5):527-34.

8. Okamoto T., Alves-Rezende MCR. Effects of tissucol and epsilon aminocaproic acid in the healing process following dental extraction in dehydrated rats. *Braz Oral Res* 2006;20(1):33-9.

9. Ruggiero SL., Fantasia J., Carlson E. Bisphosphonate-related osteonecrosis of the jaw: background and guidelines for diagnosis,staging and management . *Oral Surg Oral Med Oral Pathol Oral Radiol Endod* 2006;15(3):74-8.

10. Marx RE., Sawatari Y., Fortin M., Broumand V. Bisphosphonate-induced exposed bone (osteonecrosis/osteoporosis) of the jaws: risk factors, recognition, prevention, and treatment. *J Oral Maxillofac Surg* 2005;63(11):1567-75.

11. Marx RE., Cillo JE. JR., Ulloa JJ. Oral bisphosphonate-induced osteonecrosis: risk factors, prediction of risk using serum CTX testing, prevention and treatment. *J Oral Maxillofac Surg* 2007;65(12):2397-410.

12. Merigo E., Manfredi M., Meleti M., Corradi D., Vescovi P. Jaw bone necrosis without previous dental extractions associated with the use of bisphosphonates (pamidronate and zoledronate):a four-case report.*J Oral Pathol Med* 2005;34(10):613-7.

13. Mashiba T., Turner H., Hirano T., Forwood MR.,

Johnston Burr DB. Effects of suppressed Bone Turnover by Bisphosphonates on Microdamage. Accumulation and Biomechanical Properties in Clinically Relevant Skeletal Sites in Beagles. *Bone* 2001;28(5):524-31.

14. Gonzales-Moles MA., Bagan-Sebastian JV. Alendronate-related oral mucosa ulcerations. *J Oral PatholMed* 2000;29:514-8.

15. Grant BT., Amenedo C., Freedman K., Kraut RA. Outcomes of placing dental implants in patients taking oral bisphosphonates:a review of 115 cases. *J Oral Maxillofac Surg* 2008;66(2):223-30.

16. Diel IJ, Fogelman I., Al-Nawas B., Hoffmeister B., Migliorati C., Gligorov J., Vaananen K., Pylkkänen L. Pathophysiology, risk factors and management of bisphosphonate-associated osteonecrosis of the jaw: Is there a diverse relationship of amino- and non-aminobisphosphonates? *Crit Rev Oncol Hematol* 2007;64(3):198-207.

17. Dimitrakopoulos I., Magopoulos C., Karakasis D. Bisphosphonate-induced avascular osteonecrosis of the jaws:a clinical report of 11 cases. *Int J Oral Maxillofac Surg* 2006;35(7):588-93.

18. Hellestein JW., Marek CL.. Bisphosphonate osteochemonecrosis (bis-phossy jaw): is this phossy jaw of the 21st century? *J Oral Maxillofac Surg* 2005;63(5):682-9.

19-Abi Najm S., Lesclous P., Tommaso L., Samson J.

Ostéonécrose des maxillaires dues aux bisphosphonates(2e partie):experience genevoise. *Med Buccale Chir Buccale* 2008;14:63-84.

20. Bagan JV., Jimenez Y., Murillo J., Hernandez S., Proveda R., Sanchis JM. Jwa Osteonecrosis associated with bisphosphonates: Multiple exposed areas and its relationship to teeth extractions:Study of 20 cases. *Oral Oncol* 2006;42:327-9.

21. Carter G., Goss AN., Doecke C. Bisphosphonates and avascular necrosis of the jaw: a possible association. *Med J Aust* 2005;182:423-5.

22. Santini D., Vincenzi B., Avisati G. Pamidronate induces modifications of circulating angiogenic factors in cancer patients. *Clin Cancer Res* 2002;8:1080-1084.

23. Melo MD, Obeid G. Osteonecrosis of the jaws in patients with a history of receiving bisphosphonate therapy: strategies for prevention and early recognition. *J Am Dent Assoc* 2005;136(12):1675-81.

24. American Dental Association Council on scientific affairs- Dental management of patients receiving oral bisphosphonate therapy: expert panel recommendations. *J Am Dent Assoc* 2006;137(8):1144-50.

25. Hortobagyl GN, Theriualt RL. Long-term prevention of skeletal complications of metastatic breast cancer with pamidronate. *J Clin Oncol* 1998;16:2008.

26. Rodan R., Fleisch H. Bisphosphonates: Mechanisms of action. *J Clin Invest* 1996;97(12):2692-96.